

Thoracic Injuries

**EMS Continuing Education
Technician through Technician-Advanced Paramedic**

**Consistent with the
National Occupational Competency Profiles
as developed by
Paramedic Association of Canada
and
“An Alternate Route to Maintenance of Licensure”
as developed by Manitoba Health**

**Evaluated for content by:
Douglas Eyolfson, MD, FRCP(C)**

**Developed by:
Educational Subcommittee – Paramedic Association
of Manitoba**

Revised August 2010

Disclaimer

These documents were developed for improved accessibility to “An Alternative Route to Maintenance of Licensure” for all paramedics in Manitoba. Regional implementation of Alternate Route is at the discretion of the local EMS Director.

This is a supportive document to the National Occupational Competency Profiles and “An Alternative Route to Maintenance of Licensure.” It is not the intent that this package be used as a stand-alone teaching tool. It is understood that the user has prior learning in this subject area, and that this document is strictly for supplemental continuing medical education. To this end, the Paramedic Association of Manitoba assumes no responsibility for the completeness of information contained within this package.

It is neither the intent of this package to supercede local or provincial protocols, nor to assume responsibility for patient care issues pertaining to the information found herein. Always follow local or provincial guidelines in the care and treatment of any patient.

This package is to be used in conjunction with accepted models for education delivery and assessment, as outlined in “An Alternative Route to Maintenance of Licensure”.

This document was designed to encompass all licensed training levels in the province Technician, Technician-Paramedic, Technician-Advanced Paramedic. Paramedics are encouraged to read beyond their training levels. However, the written test will only be administered at the paramedic’s current level of practice.

All packages have been reviewed by the Paramedic Association of Manitoba’s Educational Subcommittee and physician(s) for medical content.

As the industry of EMS is as dynamic as individual patient care, the profession is constantly evolving to deliver enhanced patient care through education and standards. The Paramedic Association of Manitoba would like to thank those practitioners instrumental in the creation, distribution, and maintenance of these packages. Through your efforts, our patient care improves.

This document will be amended in as timely a manner as possible to reflect changes to the National Occupational Competency Profiles, provincial protocols/Emergency Treatment Guidelines, or the Cognitive Elements outlined in the Alternate Route document.

Any comments, suggestions, errors, omissions, or questions regarding this document may be referred to info@paramedicsofmanitoba.ca , attention Director of Education and Standards.

Thoracic Injuries

Conventions Used in this Manual

Black lettering without a border is used to denote information appropriate to the Technician Level and above.

|| Text with the single striped border on the left is information appropriate to Technician-Paramedic and above.

||| Text with the double striped border on the left is information appropriate to Technician-Advanced Paramedic and above.

Table of Contents

Disclaimer	1
Introduction.....	4
Mechanism of Injury.....	6
Inspection.....	8
Palpation	8
Percussion	8
Auscultation	8
Medications of the Trauma Patient.....	9
Pulmonary Contusion.....	15
Traumatic Asphyxia.....	16
Diaphragmatic Rupture.....	18
Injuries to Structures in the Mediastinum.....	18
Injuries to the Thoracic Spine	18
References.....	19

Introduction

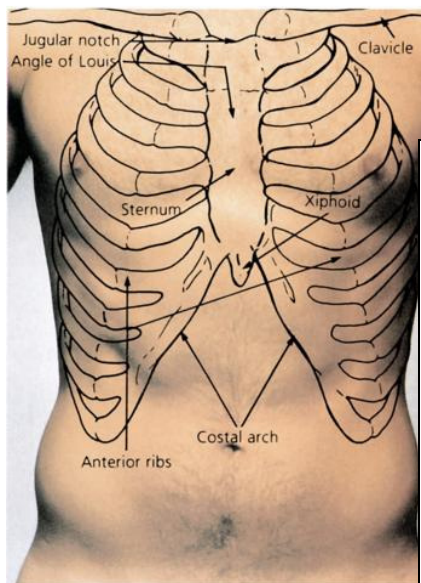
The chest, or thoracic cavity, contains the heart, lungs, major blood vessels, and associated structures. Thoracic injuries are the result of blunt trauma, penetrating trauma or both. These injuries most commonly result from motor vehicle crashes, blast injuries, falls from heights, blows to the chest, chest compression, and gunshot and stab wounds. Thoracic injuries include damage to skeletal, pulmonary, cardiac components of the chest as well as to the great vessels and/or diaphragm. A number of potentially lethal conditions may result from significant chest trauma. These include pneumothorax, tension pneumothorax, hemothorax, sucking chest wound flail chest, pericardial tamponade, myocardial and/or pulmonary contusion, cardiac tamponade, and aortic and / or diaphragmatic rupture. EMS personnel must be able to recognize and treat these injuries during the initial assessment of these patients.

General Thoracic Anatomy

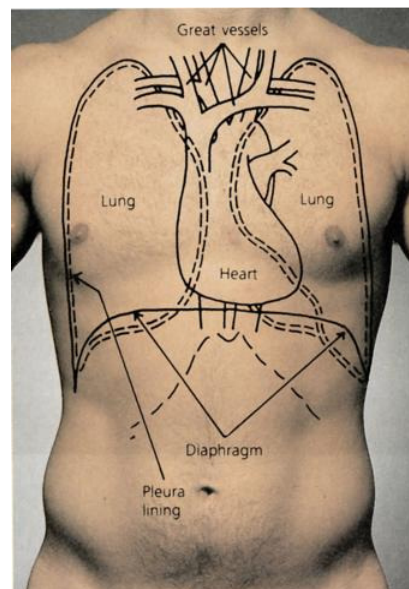
The following is a brief review of thoracic anatomy and physiology as they pertain to traumatic thoracic injury. For a more complete coverage of the skeletal, respiratory and cardiovascular components of the thoracic cavity, the reader is referred to the appropriate section of the “Musculoskeletal Injuries”, “Respiratory Emergencies” and “Cardiovascular Illnesses and Injuries” section of the ARML program respectively.

Thoracic Skeleton

The thorax is formed ventrally by the sternum and costal cartilages and dorsally by the 12 thoracic vertebrae and the dorsal parts of the 12 ribs (costa). The thorax of women has less capacity, a shorter sternum, and more moveable upper ribs than that of men. This thoracic skeletal “cage” protects vital organs within the thorax as well as covering and protecting part of the upper abdominal organs. The integrity of the thoracic skeleton is vital as it provides support for respiratory movements of the diaphragm and intercostal muscles and prevents the collapse of the thorax during respiration. The intercostal neurovascular bundle runs along the inferior surface of each rib.



The organs within the chest are protected by the ribs, which are connected in the back by the vertebrae and in front, through costal cartilages, to the sternum



A view of the anterior aspect of the chest, showing the position of the heart, lungs, and diaphragm.

Respiratory Components of the Thoracic Cavity

The thoracic cavity is lined with the pleura, which is a thin, two-layered membrane. The outer layer (parietal pleura) adheres to the inner thoracic wall and upper surface of the diaphragm. The inner layer (visceral pleura) covers the surface of the lungs. The parietal and visceral pleurae are separated by a small amount of pleural fluid, which acts as a lubricant during expansion and contraction of the lungs. If the pleural lining is damaged by traumatic injury, respiratory function may be severely compromised.

The thoracic components of the respiratory system include the trachea, bronchi and lungs. The trachea is a 10 – 12 centimeter-long tube that connects the larynx to the two mainstem bronchi. The tracheal lumen is supported by cartilaginous, C-shaped rings that help keep the airway patent (open). The point at which the trachea divides, or bifurcates, into the right and left mainstem bronchi is called the carina. The mainstem bronchi enter the lung tissue at the hilum, and then divide into smaller and smaller bronchi, eventually ending as respiratory bronchi which terminate in the alveoli. The alveoli are the functional units of the lungs and as such, are the core of the lung parenchyma (tissue). The hollow alveoli resist collapse because of the presence of surfactant, a chemical that decreases surface tension and makes it easier for them to expand. Traumatic injury may cause alveolar collapse (atelectasis) and/or bleeding in the lungs, both of which decrease or stop gas exchange in the lungs. The right lung has three lobes, and the left lung (which shares thoracic space with the heart) has two lobes.

The base of the thoracic cavity is formed by the diaphragm, a dome-shaped muscle beneath the lungs. Contraction of the diaphragm, along with contraction of the intercostal muscles, expands the chest cavity, thus decreasing intra-thoracic pressure and drawing air in during inspiration.

Any trauma to the supportive structures, as well as to the lung parenchyma itself, will interfere with the respiratory process. EMS personnel should also be aware that the pediatric airway is different in terms of the relative size and position of some of its components. These differences between respiratory anatomy in adult and pediatric patients should be considered when assessing and treating thoracic injuries in pediatric versus adult patients.

Cardiovascular Components of the Thoracic Cavity

As is the case with the lungs, the heart is enclosed in a two-layered membrane – the pericardium. The outer, parietal pericardium, which lines the fibrous pericardial sac, and the inner visceral pericardium, which covers the surface of the heart. A small amount of lubricating fluid fills the slit-like space (the pericardial space) between the two pericardial layers.

The heart itself lies obliquely in the mediastinum; behind the sternum, between the lungs, and just above the diaphragm. The base (top) of the heart is approximately level with the second intercostal space and the apex (bottom) is about the level of the fifth intercostal space, at the mid-clavicular line. In most people, two thirds of the heart's mass is located to the left of the sternum (this is reversed in a small percentage of the population). The great vessels are the major arteries and veins which enter and leave the heart and lungs (aorta, superior and inferior vena cavae, and the pulmonary arteries and veins). Other major arteries found within the chest cavity are: the brachiocephalic, left subclavian, left common carotid. Knowing the location of the heart and

great vessels within the thoracic cavity can help EMS personnel assess possible injuries from blunt or penetrating trauma to the chest.

The interconnection between the respiration and circulation is important bear in mind when treating thoracic trauma patients.

Associated Abdominal Structures

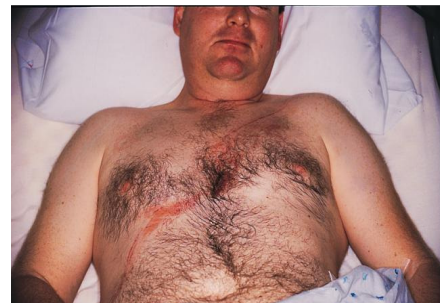
The upper abdominal organs, including the spleen, liver, kidneys, pancreas, and stomach, are protected by the lower rib cage. Any patient with a penetrating thoracic wound at the level of the nipples (fourth intercostals space) or lower should be assumed to have an abdominal injury as well as a thoracic injury.

Mechanism of Injury

The most common mechanisms of injury in the civilian population are: blunt trauma (falls, industrial accidents); penetrating trauma (gunshot wounds, stabbings); combined blunt and penetrating (MVC's); other (medical etiologies such as spontaneous rupture).

An understanding of the kinematics of trauma will help EMS personnel assess the traumatically injured patient. Always take the time to evaluate the scene and try to determine mechanism of injury. This will allow the paramedic to find not only the obvious injuries, but hidden ones as well. For example, when treating patients involved in motor vehicle collisions, consider the following:

- Where in the car was the patient?
- Was the patient wearing a seatbelt? (the seatbelt itself can both cause, and prevent, chest trauma)
- Were airbags involved either in preventing or causing injury?
- Were there two or more vehicles?
- Was the steering wheel bent?
- What amount of energy impacted the patient (what was the speed and direction of the collision)?
- What are the other patients' injuries?
- Was the patient ejected?
- What might the injuries be if the patient was driving a motorcycle, ATV or snowmobile?
- Where any pedestrians involved?
- Are there multiple patients?



Chest injury resulting from seatbelt use.

Other factors affecting injury patterns are: length of time before EMS treatment; ambient weather conditions; age of the patient, pre-existing illness; and other factors, for example, is the patient pregnant; etc. Traumatic forces applied to organs may cause solid organs to tear, and hollow organs to rupture.

Blunt trauma due to compression injury to the thorax frequently involves the heart and lungs. Associated injuries to external structures include fractured ribs and sternum, which can lead to an unstable chest wall, pneumothorax due to a penetrating rib, or both. Compression of the patient's heart between the sternum and the vertebral column can cause: cardiac dysrhythmias, myocardial contusion, atrial or ventricular rupture, and any combination of these.

Penetrating chest trauma almost always causes a pneumothorax with a 75% likelihood of an associated hemothorax. The character of the penetrating object, its speed of penetration, and the type of body tissue it passes through, or into, determines if the force is of the crushing or stretching variety. Gunshot wounds, for example, can cause damage to major vessels, lung tissue, or the heart itself. On occasion, a damaged lung may not be able to expel air from the chest cavity causing the eventual collapse of the lung and shift in the mediastinum (tension pneumothorax). Be wary of the gunshot wound to the abdomen, as the chest cavity may be penetrated, depending on the direction of the bullet. Knowledge of the type of weapon used in gunshot wounds is useful in determining possible injuries. In addition, bullets (or other penetrating objects) can fragment and embolize. It is important to remember that any penetrating injury to the fourth intercostal space, or below, may well have passed through the diaphragm, resulting in the possibility of trauma to the abdominal organs.

Signs and Symptoms of Thoracic Injuries

Thoracic trauma is often associated with multisystemic injury and the patient may have multiple complaints. Due to the fact that injuries to the chest have the potential to become life-threatening, EMS personnel should concentrate on the ABC's when assessing a trauma patient. Signs and symptoms associated with thoracic injuries include:

- Pain, especially on inspiration and/or expiration
- Dyspnea and/or rapid, shallow breaths
- Paradoxical breathing and/or asymmetry in the chest
- Diminished or absent breath sounds
- Neck vein distention
- Tracheal shift from mid line
- Gurgling sounds with sucking chest wounds
- Shock and hypoxia
- Altered or decreasing level of consciousness

Assessment of Thoracic Injuries

Understanding the structure of the thoracic cage and its role in respiration is vital to performing an adequate trauma assessment of the chest. A loss of thoracic structural integrity prevents or limits respiratory function. In addition, it is important to understand how traumatic damage may affect the sound or feel of the thorax during inspiration and expiration.

Inspection

The chest wall should be inspected for symmetry on both the anterior and posterior surfaces. Although the thorax is not completely symmetrical, a visual inspection of one side should offer reasonable comparison to the other. Bear in mind that conditions such as Chronic Obstructive Pulmonary Disease may alter the overall shape of the chest. The paramedic should also observe the chest for skin pallor, cyanosis, suture lines from surgery or evidence of implanted pacemakers or central venous lines, and any accessory muscle use. Again, the rate, rhythm and quality of respirations should be reassessed at this time.

Palpation

The thorax should be palpated for tenderness, crepitus, subcutaneous emphysema, depressions, and unusual movement. The clavicles should be evaluated for symmetry and integrity and the trachea assessed for position. As the patient inhales and exhales, palpation should be used to assess equal chest rise and pain during respirations.

Percussion

Percussion is an acquired skill made more difficult by loud background noises in the prehospital setting. Resonance is usually heard over all healthy lung fields. Hyperresonance is associated with hyperinflation and may indicate asthma, pneumothorax, or pulmonary disease. Dullness suggests the presence of fluid or congestion such as hemothorax or pneumonia.

Auscultation

The thorax is best auscultated with the patient sitting upright (when possible) and breathing slowly and deeply through an open mouth. Lung sounds are best observed with the stethoscope directly against the patient's skin, auscultating both anteriorly and posteriorly when possible in a quiet environment.

Medications of the Trauma Patient

Consideration needs to be given to the trauma patient's prescribed medications as they may indicate that a medical condition might have precipitated the traumatic injury. An awareness of the patient's medications may also aid paramedics in the treatment of a trauma patient. For example, did the patient on Dilantin have a seizure prior to the MVC? Is his level of consciousness after the incident consistent with postictal behavior or as a direct result of his injuries? If a trauma patient is taking blood-thinning medications such as ASA, coumadin (Warfarin) or clopidogrel (Plavix), would this impact your treatment considerations? Does the presence of metered-dose inhalers (Ventolin or Atrovent) affect your working diagnoses of the chest trauma patient?

Information regarding the medical history of the trauma patient may also be important to the treatment of trauma patients. This information may be obtained from family, friends, co-workers, or from medication (prescription or over-the-counter) bottles, and MedicAlert identification. The paramedic should take the time to obtain this information whenever possible.

General Treatment of Thoracic Injuries

The general components of good emergency care for patients with thoracic injuries are listed below. For more detailed treatment procedures, please refer to the Manitoba Health Emergency Treatment Guidelines for "Chest Injuries" (T7).

Primary Survey: assess for and treat any immediate life threats.

Note: Load and go should be initiated as soon as any life-threatening condition is identified.

- provide high concentration oxygen and assist ventilations as required
- treat for shock if indicated
- do not allow the patient to exert him/herself
- initiate transport (keep on scene times to a minimum)

If patient has increasing respiratory distress, exhibits signs/symptoms of hypoxia, or has a decreasing level of consciousness, ventilation should be supported using 100% oxygen via a bag-valve mask. Monitor closely for pneumothorax.

Secondary Survey: may need to be conducted en route if patient's condition requires immediate transport.

Treat other injuries as indicated, if patient's condition permits
Re-assess vital signs frequently

Anticipate IV starts and/or intubation if trained to do so.

Traumatic Thoracic Injury Fatalities

Deaths from trauma occur in three periods: immediate, early, and late.

Immediate death occurs within seconds or minutes of the injury. Lacerations of the brain, brain stem, upper spinal cord, heart, aorta, or other large vessels usually cause these deaths. Few if any of these patients can be saved.

Paramedics can have a bigger impact on those patients likely to die within the early period. The causes of these deaths usually are major head injury, hemothorax, ruptured spleen, lacerated liver, pelvic fractures or multiple injuries associated with significant blood loss. Most of these injuries are treatable, but the time lapse between injury and definitive care is critical. Paramedics must recognize patients in this category and provide rapid assessment, stabilization of life-threatening injuries, and rapid transportation to the appropriate medical facility for definitive care.

Patients who die in the late phase usually succumb to sepsis, infection, or multiple organ failure days or weeks after the event.

Pneumothorax

Pneumothorax means the presence of air in the pleural space, usually resulting in some degree of lung collapse.

Consider, for example, the non-seatbelted driver of the vehicle in a high-speed crash. This mechanism of injury can have a significant effect on expansion (inspiration) and relaxation (expiration) of the lungs during respiration. In this case, efficient respiration may fail because of loss of pleural seal integrity. If an internal or external wound allows air, blood, or fluid to enter the pleural space, this potential space becomes an actual space which reduces effective lung expansion, thereby compromising respiration. If the pleural space expands because of air from an interior wound, it is called a closed pneumothorax. If the wound is external, it is called an open pneumothorax. The opening may be the result of tracheal injury, a torn bronchus, bronchiole, or alveolus due to the impact of the chest against the steering wheel, which was bent in the introductory scenario. The opening may also be caused by penetrating trauma, COPD, or congenital defect. The larger the tear and the structure involved, the more rapid the progression of the pneumothorax. In small tears, the pneumothorax may self-seal, and the body will reabsorb the air. Penetrating trauma (open pneumothorax) will usually require a rather large hole to allow the exchange or passage of air. Such trauma normally results in gurgling or frothy blood at the wound site (thus the term sucking chest wound).

Compression of a hyperinflated chest against the steering wheel of the truck may precipitate a pneumothorax. If a driver sees the impending impact of his/her vehicle in an accident, he/she takes a deep gasp of air and holds it. During the crash, the chest impacts the steering wheel and compresses the hyperinflated thorax against the closed glottis. The alveoli and bronchioles rupture like a sealed paper bag between two hands clapping. This phenomenon, called the paper bag syndrome, results in a closed pneumothorax.

Victims of this type of trauma may present with chest pain, respiratory distress (dyspnea), an increased heart rate and a normal blood pressure. The pain may be sharp or pleuritic (increasing with respiration) in nature. Progressively, the patient may develop subcutaneous emphysema or tracheal deviation towards the injured side. Decreased air entry on auscultation to the injured side is also a common exam finding.

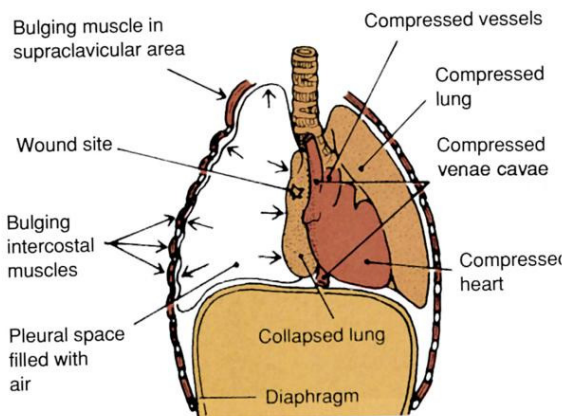
Appropriate emergency care for these and all suspected pneumothorax patients includes: caring for the ABC's, maintaining C-spine control, giving high concentration oxygen, establishing IV access (per local protocol), monitoring vital signs (paying particular attention to respirations) and monitoring EKG. EMS personnel should also obtain a relevant history, position the patient in the most comfortable semi-Fowlers position possible, supported towards the injured side if tolerated and permitted by injuries.

An open pneumothorax should be dressed with an occlusive dressing and sealed on 3 sides. An airtight dressing which is sealed on 3 sides acts as a one-way valve, allowing air to exit the pleural space on expiration, but preventing air from entering on inspiration. Properly dressing this type of wound should help prevent a tension pneumothorax from developing.

Tension Pneumothorax

If a wound permits air to enter the pleural space, it may also act as a one-way valve (allowing air in, but not allowing it out), producing a condition called tension pneumothorax. Tension pneumothorax is a progressive pneumothorax that enlarges, builds in pressure, and begins to infringe upon the function of the opposite lung as well as the circulatory system. The valve allows air to enter the pleural space during inspiration. As the patient breathes out, the valve closes and air cannot exit. As this problem progresses, pressure within the thorax grows. This increase in intrathoracic pressure will:

- Increase the effort of respiration.
- Push the mediastinum against the unaffected lung.
- Retard venous return to the heart.
- Possibly kink the vena cava where it travels through the diaphragm.



A tension pneumothorax can develop if a penetrating chest wound is bandaged tightly and air from a damaged lung cannot escape. The air then accumulates in the pleural space.

Overall, a tension pneumothorax will cause extreme dyspnea and, eventually, acute circulatory compromise. In this scenario, the combination of the occlusive dressings and the patient positioning against the stretcher did not allow air to escape from the pleural space, causing the tension pneumothorax. Additional signs and symptoms may include: markedly decreased or absent air entry on the injured side possibly coupled with hyper resonance on percussion, distended neck veins, hypotension, subcutaneous emphysema, and an affected side that may look fuller and move less with breathing.

Movement of the mediastinum away from the affected side may cause the trachea to shift from midline. It is a late sign, present only after there has been significant shifting of the mediastinum. Therefore, tracheal deviation is not a good sign to guide care.

Consider maintaining the airway with a combitube or endotracheal tube as required. Manage circulatory compromise with IV fluids, and patient positioning as tolerated.

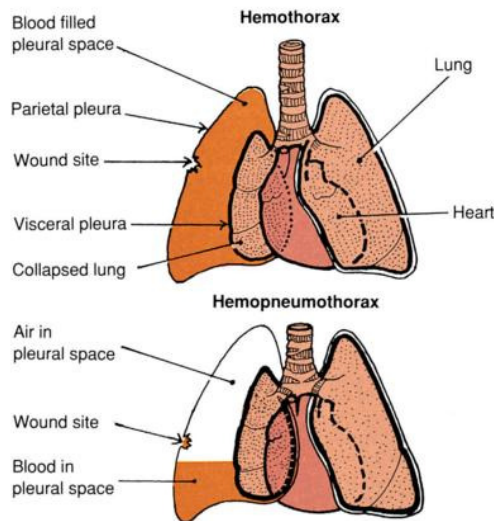
If a tension pneumothorax is suspected, and appropriately trained EMS personnel are attending, the next intervention must be the insertion of a small cannula (typically a 14-gauge intravenous catheter) through the chest wall into the pleural space. The purpose of this intervention is to convert the tension pneumothorax into an open pneumothorax. Although the classic description of this maneuver places the insertion point at the second intercostal space in the midclavicular line, any point in the superior, anterior, or lateral chest wall may be selected. Once the tension pneumothorax is decompressed (a hiss of gas exiting the pleural space may be audible) the patient's perfusion often improves within seconds.

A tension pneumothorax that does not respond to needle decompression or the continuous flow of air from the needle following decompression should alert the paramedic to the possibility of a tracheobronchial injury. These are characterized by: severe hypoxia, tachypnea, tachycardia, massive subcutaneous emphysema, and hemoptysis. Even though tracheobronchial insult is rare (less than 3% of blunt or penetrating chest trauma), they carry a 30% mortality rate.

Hemothorax

A hemothorax occurs when a blood vessel in the chest cavity is severed and blood begins to accumulate in the pleural space. It can be the result of penetrating or blunt trauma and can cause severe shock. Both hemothorax and pneumothorax can occur independently or in combination. A penetrating wound is likely to result in both. The accumulation of blood in the pleural space will normally be slow and result in minimal respiratory compromise during the time the patient is in the prehospital setting. If, however, the hemothorax involves a large vessel, blood loss may be severe and hypovolemia will be the primary patient problem. Remember that each lung occupies about 3 to 4 liters of space. Any rapid blood loss capable of causing respiratory compromise will probably result in hypovolemic shock. Therefore, recognition of hemothorax in the prehospital phase is extremely difficult. Larger blood vessels, such as the intercostal artery, can bleed at a rate of 50 ml per minute.

In circumstances where a hemothorax occurs as a result of penetrating chest injuries, it will be almost impossible to differentiate from pneumothorax. Frequently both air and blood occupy the pleural space, creating a hemopneumothorax. Once again, it is important to recognize and treat the signs of symptoms of the condition.



A hemothorax is a collection of blood in the pleural space produced by lacerated blood vessels within the chest.

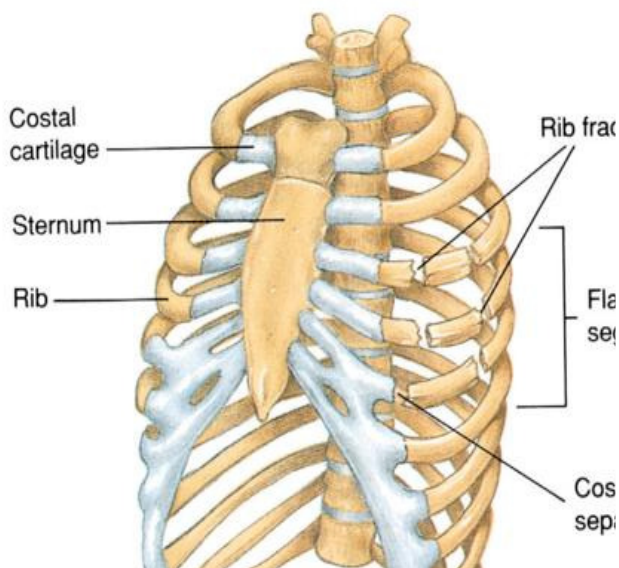
A large (32 to 40 French) chest tube is ideal for draining a hemothorax. It should be inserted in the anterior axillary line at the 4th or 5th intercostal space. If the hemothorax persists after insertion and there is minimal drainage from the tube, the chest tube is either occluded by clots or not inserted in the proper area. Occasionally, when the chest tube is initially inserted, blood emerges at an alarmingly rapid rate. If the patient's condition improves as blood is being removed, continuing drainage and observation of the patient is acceptable. However, if the patient and their vital signs deteriorate as the blood is being removed, loss of the tamponading effect of the hemothorax has probably allowed serious bleeding from the lung to recur. In those circumstances, the tube should be clamped off, and the patient taken for emergency surgery.

Flail Chest

Rib fractures are the most common thoracic injury. Flail chest refers to an injury where two or more ribs are fractured in two or more places resulting in a free-floating segment of the chest wall. The portion that is unsupported moves in a paradoxical fashion (expanding or bulging out during expiration and collapsing during inhalation).

Although the paradoxical motion of the involved chest wall can greatly increase the work of breathing, the main cause of hypoxemia in a case of flail chest is the underlying lung contusion. Treatment for flail chest involves applying gentle pressure, as with a bulky trauma pillow, to inhibit the outward excursion of the segment. Although this reduces vital capacity, it can relieve some of the pain and it increases the efficiency of ventilation. Paradoxical chest movement is

typically not seen initially, but develops over time. In children, significant intrathoracic injury may be present without rib fracture due to rib cage elasticity.



When three or more adjacent ribs are fractured in two or more places, a flail chest results. This segment will move paradoxically when the patient breathes.

Although the paradoxical motion of the involved chest wall can greatly increase the work of breathing, the main cause of hypoxemia in a case of flail chest is the underlying lung contusion. Displaced fractures may perforate the lung, liver or spleen. Fracture of the first three ribs generally indicates a severe blow to the chest, and other injuries such as bronchial tear or aortic laceration should be suspected. Paradoxical chest movement is typically not seen initially, but develops over time.

Emergency care for flail chest includes:

Establishing ABC's - assist ventilations if required; administer O₂ - high concentration; bind a small pillow, or heavy dressing over flail segment at beginning of inspiration; (although this reduces vital capacity, it can relieve some of the pain and increase the efficiency of ventilation). Establish I.V. access as per local protocols; monitor respirations and cardiac function closely; obtain vital signs and relevant history; and transport patient in most comfortable position, towards injured side if possible.

Mechanism of injury, such as rapid deceleration from an MVC that produces chest injuries such as a flail chest may also cause stretching and shearing trauma within the lung itself. Fixed and mobile structures within the lung move at different speeds during inertial deceleration, resulting in rupture of the alveoli with associated hemorrhage producing a pulmonary contusion. Effects on the patient include shortness of breath, tachycardia, cough, hemoptysis, and cyanosis, which are directly proportional to the size of the underlying contusion. These effects are due to the interstitial and intra-alveolar bleeding, potentially causing profound hypoxemia.

As pulmonary contusions are commonly associated with other thoracic injuries, care of these patients involves effective ABC and hypovolemia management, providing high flow oxygen, and

treating the primary injuries. Considering that over 50% of blunt trauma injuries include pulmonary contusion, EMS personnel should appreciate the kinematics involved in the incident to aid in diagnosing these conditions.

Many authorities recommend intubation and positive pressure ventilation (internal splinting) in patients with respiratory distress and a flail chest, especially in the presence of shock, head injury or pulmonary disease. Intubating the hypovolemic trauma patient is not without its risks. It is not uncommon for these patients to arrest within a short timeframe. Hypovolemic patients who are intubated and vigorously ventilated may experience decreased venous return, leading to cardiac arrest. Initial ventilations should be at 10-14 breaths per minute, at a tidal volume of 5-8 ml/kg. Excessive ventilatory pressures may also cause a tension pneumothorax to the injured lung. Even if the lungs are normal, ventilatory pressures of 70 to 80 cmH₂O can cause pulmonary damage.

Pulmonary Contusion

During trauma, compression of the chest may contuse the lungs as it would any other body tissue. Pulmonary tissue will swell and edema develops, much like tissue anywhere else in the body. Pulmonary contusion probably occurs to a varying degree in all thoracic injuries and is a major component of flail chest. Pulmonary contusion reduces lung compliance and increases respiratory effort. Patients often exhibit hypoventilation. It also interferes with the diffusion of carbon dioxide, increasing PaCO₂ and decreasing the blood's pH.

Myocardial Contusion

The clinical findings of myocardial contusion (blunt myocardial injury) are often subtle and frequently overlooked for the following reasons: multiple injuries direct attention elsewhere, there is often little evidence of thoracic injury, and signs of cardiac injury may not be present on initial exam. Contusions to the myocardium usually result from motor vehicle collisions as the chest wall strikes the dashboard or steering column. A deformed dashboard or steering wheel should alert the paramedic to the possibility of a cardiac injury.

The extent of injury may vary from a localized bruise to a full-thickness injury to the wall of the heart with hemorrhage and edema. The accumulation of blood in the pericardial space (hemopericardium) may result from a lacerated epicardium or endocardium, and could eventually cause cardiac rupture or traumatic myocardial infarction. Patients with this condition may present with chest pain (similar to myocardial infarction), dysrhythmias (such as persistent tachycardia), evidence of cardiogenic shock, or they may be asymptomatic.

Management of myocardial contusion is similar to that of pneumothorax, with the inclusion of managing any dysrhythmias and hypotension if they present.

Any pharmacological interventions that advanced care paramedics may provide for dysrhythmias and hypotension must not increase myocardial oxygen demand in these patients.

Traumatic Asphyxia

Traumatic asphyxia is a severe crushing injury to the chest and abdomen that results from an increase in intrathoracic pressure which forces blood from the right side of the heart into the veins of the upper thorax, neck, and face. Most patients who have experienced this type of severe compression injury to the chest will likely present in cardiorespiratory arrest.

Compression of the chest severely limits chest excursion and results in hypoventilation. It also may tamponade intrathoracic hemorrhage and cause a backflow and back up of venous blood, especially within the neck and the head. The classical presentation of traumatic asphyxia includes bloodshot eyes, bulging blue tongue, distended neck veins, and a cyanotic upper body. Chest deformity or bloody vomitus may also be present. However, keep in mind that initially these signs and symptoms may be absent and the patient may appear free of trauma, other than being breathless and pulseless. Mechanism of injury in this case is the only clue as to what the problem may be. In either case the prognosis is grave. While release of the chest pressure may help the patient to breathe, it may also lead to rapid hypovolemia, shock and death. Therefore, keep in mind that a patient who is trapped under a heavy object, may require that you do as much preventative care as possible, prior to removing the object. For example, a patient trapped under a fallen tree, should have patent airway established, high-flow oxygen provided, and an I.V. infusion established prior to removal of tree off their chest. These preventative measures may help avoid the rapid hypovolemia, and shock from developing. Treatment may also involve the relief of a tension pneumothorax if found.

Pericardial Tamponade

Penetrating trauma (and rarely blunt trauma) may cause tears in the heart chamber walls, allowing blood to leak from the heart. This trauma may also lacerate coronary arteries, permitting blood to leak into the pericardium. If the trauma tears the pericardium, the patient rapidly exsanguinates. However, the fibrous pericardium may remain intact, allowing blood to enter the pericardial space, thus causing an increased pericardial pressure. This increased pressure does not allow the heart to expand and refill with blood, resulting in a decrease in cardiac output and stroke volume. This condition is known as pericardial tamponade.

Most patients with pericardial tamponade initially demonstrate peripheral vasoconstriction (which tends to raise the diastolic blood pressure more than the systolic blood pressure, causing a decrease in pulse pressure) and an increase in heart rate to compensate for the decreased cardiac output.

Beck's triad is a combination of three symptoms that characterize cardiac tamponade: elevated central venous pressure (evidenced by JVD), muffled heart sounds and hypotension. It is important to note; however, that only 30% of pericardial tamponade patients will present in this fashion. JVD is the best way to distinguish tamponade from hypovolemic shock when the mechanism of injury may indicate either injury.

Pericardial tamponade is a true emergency as cardiac arrest due to tamponade is unresponsive to CPR, defibrillation and drug therapy. These patients must have pericardial blood removed and the source of the bleeding stopped to survive the injury. Pre-hospital management includes careful monitoring, high flow oxygen administration, fluid replacement, and rapid transport to hospital where needle pericardiocentesis can be performed to aspirate blood from the pericardial sac. Removal of as little as 20 ml of blood from the pericardial sac may drastically improve cardiac output.

The EKG usually shows low-voltage QRS complexes (less than 0.7 mV) and ST-segment elevation (due to the inflammation of the epicardium) with PR-segment depression, as in pericarditis. Electrical alternans (beat-to-beat variation in the amplitude of the P and R waves unrelated to the respiratory cycles) is a classic but uncommon finding (about 20 percent of cases).

Aortic Rupture (Traumatic Aortic Laceration)

Aortic rupture is a sudden tearing of the aorta, usually at a point of attachment (such as the ligamentum arteriosum). Prognosis for these patients is grave and 80 – 90 % of patients with traumatic aortic rupture die before emergency treatment can be instituted. Common mechanisms that produce this type of injury are: shearing forces generated by abrupt thoracic deceleration in a motor vehicle accident, or by pinching the aorta between the anterior and posterior components of the bony thorax when the chest is compressed in crush injuries and falls from a height. It is estimated that one out of six people who die in MVA's sustains this type of injury. The majority of those patients die immediately due to severe hypovolemic shock. About 10% may survive the first hour if the internal bleeding is temporarily tamponaded. Of all blunt trauma deaths, 15% are due to aortic rupture. The paramedic should always consider this type of injury when unexplained shock is encountered with appropriate mechanism of injury (for example, rapid deceleration).

Infrequent assessment findings may include: upper extremity hypertension with absent or diminished femoral pulses, paraplegia with a normal cervical and thoracic spine (due to decreased blood flow to the anterior spinal artery, which is fed from the aorta), or a harsh systolic murmur over the pericardium or interscapular region.

The usual site of damage to the aorta is in the distal arch proximal to the ligamentum arteriosum. The ligamentum arteriosum and descending thoracic arch are relatively fixed, while the transverse portion of the arch is relatively mobile. If shearing forces exceed the tensile strength of the arch, the junction of the mobile and fixed points of attachment may partially be torn. If the outer layer of tissue surrounding the aorta remains intact, the patient may survive long enough for surgical repair.

Prehospital management of these patients includes advising the appropriate receiving facility and providing rapid transport to that hospital while maintaining the ABC's and delivering high flow oxygen. Aggressive IV fluid therapy may cause an increase in pressure of the aortic wall, and; therefore, should be used cautiously with relatively normotensive patients.

Several other great vessels, such as the pulmonary arteries and veins, superior and inferior vena cava, and the aortic branches run through the thoracic cavity. Wounds sustained to these vessels typically present as significant hemothoraces and hypovolemia and should be treated accordingly.

Diaphragmatic Rupture

When rapid compression of the abdomen results in a sharp increase in intra-abdominal pressure, the pressure differences may cause the diaphragm to rupture, allowing abdominal contents into the thoracic cavity. Diaphragmatic rupture is more common on the left side, as the liver tends to protect the right side. Usually, the stomach herniates and undergoes volvulus, massively dilates, and causes lung collapse and mediastinal shift to the right. Penetrating diaphragmatic tears are more common, smaller, and therefore less detectable in the prehospital setting, but blunt diaphragmatic rupture is typically larger. Once abdominal organs enter the thoracic cavity, they may cause compression of the lung (with a reduction in ventilation), a decrease in venous return, decreased cardiac output, and shock. Occasionally, bowel sounds may be heard on chest auscultation when abdominal organs are present in the thoracic cavity. With this in mind, positive pressure ventilation that allows air to enter the stomach may, in fact, worsen the patient's condition by hyperinflating the stomach, putting more pressure on the affected lung.

Injuries to Structures in the Mediastinum

Blunt injury to the esophagus is rare; penetrating trauma, such as a knife wounds are more common. Esophageal injury may allow gastric or other foreign materials into the mediastinum; however, management of associated trauma, especially of airway and vascular structures, is generally more pressing than the esophageal wound itself. Esophageal injury may become lethal if unrecognized in the hospital.

Other injuries of the mediastinal contents include: rupture of esophagus or trachea and laceration to the inferior or superior vena cava. A tracheal/bronchial laceration may allow free air into the mediastinum, especially if the patient coughs or is placed on IPPV. Esophageal injury may allow gastric or other foreign materials into the mediastinum.

Injuries to the Thoracic Spine

Trauma victims with fractures of the thoracic spine often (about 60% of patients) have associated neurologic deficits. The high incidence may be related to the narrow diameter of the thoracic spinal canal and the potential for damage to the vascular supply to the cord.. Patients with traumatic injuries to the upper thoracic spine may have neck injuries and should be carefully assessed.

References

“An Alternative Route to Maintenance of Licensure”, Manitoba Health Emergency Services, 2001

“National Occupational Competency Profiles”, Paramedic Association of Canada, Revised June 2001

“Mosby’s Paramedic Textbook”, Second Edition, Mick J. Sanders, Mosby, Inc., c 2000

“Emergency Medicine Plus”, Version 2.0 CD, Tintinalli, McGraw Hill, c 2000

“Basic Trauma Life Support” Second Edition, Brady, John Emory Campbell, MD, Prentice Hall, Inc. c 1988

“Manitoba Health Emergency Treatment Guidelines, Chest Injuries”, Manitoba Health Emergency Services, 2006